Ischemic colitis

Dr. Mozhde Mosalla

Firouzgar Hospital

Iran University of Medical sciences

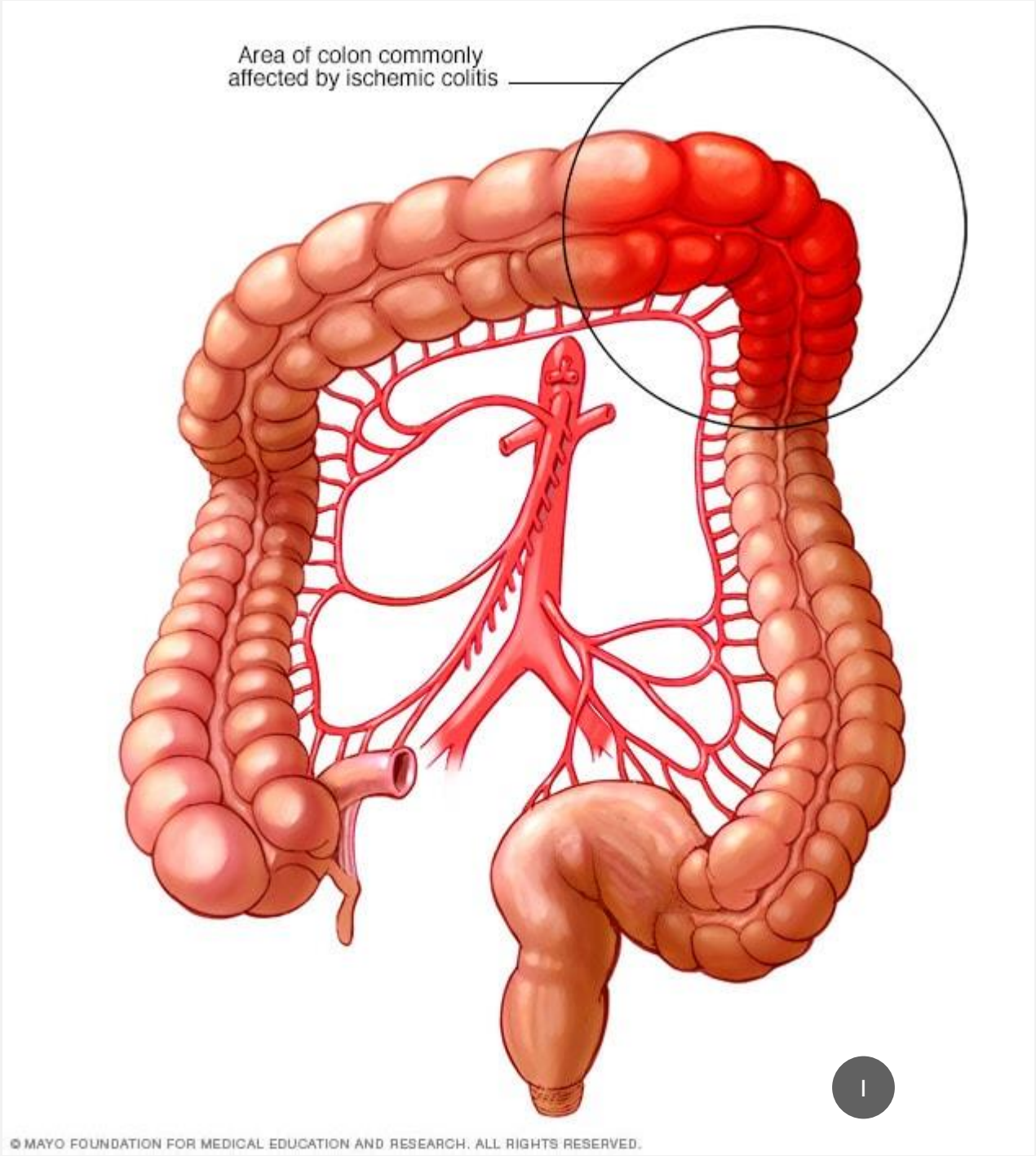

© MAYO FOUNDATION FOR MEDICAL EDUCATION AND RESEARCH. ALL RIGHTS RESERVED.

World Journal of Gastroenterology

Submit a Manuscript: https://www.f6publishing.com

World J Gastroenterol 2021 August 7; 27(29): 4746-4762

DOI: 10.3748/wjg.v27.i29.4746

ISSN 1007-9327 (print) ISSN 2219-2840 (online)

REVIEW

Ischemic bowel disease in 2021

Online Submissions: wjg.wjgnet.com
wjg@wjgnet.com
doi:10.3748/wjg.14.7302

World J Gastroenterol 2008 December 28; 14(48): 7302-7308
World Journal of Gastroenterology ISSN 1007-9327
© 2008 The WJG Press. All rights reserved.

TOPIC HIGHLIGHT

Ioannis E Koutroubakis, MD, PhD, Assistant Professor of Medicine, *Series Editor*

Ischemic colitis: Clinical practice in diagnosis and treatment

Usefulness of colonoscopy in ischemic colitis

M. Lozano-Maya, A. Ponferrada-Díaz, C. González-Asanza, O. Nogales-Rincón, C. Senent-Sánchez, V. Pérez-de-Ayala, P. Jiménez-Aleixandre, E. Cos-Arregui and P. Menchén-Fernández-Pacheco

ScientificScholar®
Knowledge is power
Publisher of Scientific Journals

www.clinicalimagingscience.org

Journal of Clinical Imaging Science



Case Report

Phlebosclerotic Colitis – An Enigma Among Ischemic Colitis

Colonic ischemia

Authors:
Peter Grubel, MD
J Thomas Lamont, MD
Govind Nandakumar, MD, FACS, FASCRS, FSSO
Section Editors:
John F Eidt, MD
Joseph L Mills, Sr, MD
Martin Weiser, MD
Deputy Editor:
Kathryn A Collins, MD, PhD, FACS

Literature review current through: Mar 2025. | **This topic last updated:** Jul 16, 2024.

Journal of Visceral Surgery (2013) 150, 19–28

ELSEVIER MASSON

Available online at
SciVerse ScienceDirect
www.sciencedirect.com

Elsevier Masson France
EM|consulte
www.em-consulte.com/en



REVIEW

Ischemic colitis: The ABCs of diagnosis and surgical management

D. Moszkowicz, A. Mariani, C. Trésallet, F. Menegaux*

ACG Clinical Guideline: Epidemiology, Risk Factors, Patterns of Presentation, Diagnosis, and Management of Colon Ischemia (CI)

Lawrence J. Brandt, MD, MACG, AGAF, FASGE[1], Paul Feuerstadt, MD, FACG[2], George F. Longstreth, MD, FACG, AGAF[3] and Scott J. Boley, MD, FACS[4]

Am J Gastroenterol 2015; 110:18–44; doi:10.1038/ajg.2014.395; published online 23 December 2014

INTRODUCTION

Ischemic bowel disease (ISBODI) is the **most common vascular disorder** of the gastrointestinal tract.

ISBODI is not that common in clinical practice, the morbidity and mortality can be high.

ISBODI results from inadequate supply of oxygenated blood to any part of the bowel wall and can be divided into small intestinal ischemia or mesenteric ischemia, and large intestinal ischemia or ischemic colitis (IC).

INTRODUCTION

Epidemiology

CI is the most common entity of ISBODI and most often affecting **older** adults and may be more prevalent in **females**.

One study showed that the overall incidence of CI was about 6.1 cases *per* 100000 person-years in 1976-1980 and it **increased** by about 4-fold to 22.9/100000 person-years over the course of few decades.

RISK FACTORS

1. Comorbid cardiovascular disease and diabetes mellitus should increase consideration of CI in patients with typical clinical features.

2. A history of IBS and constipation should be sought in patients suspected to have CI

3. Chronic kidney disease is associated with increased mortality from CI

4. Surgical procedures in which the inferior mesenteric artery (IMA) has been sacrificed, such as abdominal aortic aneurysm repair and other abdominal operations, should increase consideration of CI in patients with typical clinical features

5. In patients suspected of having CI, a history of medication and drug use is important, especially constipation-inducing medications, immunomodulators, and illicit drugs

RISK FACTORS

Drug effects

Myocardial infarction

Hemodialysis

Aortoiliac instrumentation/surgery Following, the passage of bloody stools, unexplained failure of postoperative progress, lactic acidosis, fever, leukocytosis, or thrombocytopenia should raise suspicion for colonic ischemia

Cardiopulmonary bypass

Extreme exercise

Mesenteric arteriovenous fistula or malformation

Acquired or hereditary thrombophilia

Following colonoscopy

Severe COVID-19 infection

Mesenteric venous thrombosis
Hypercoagulable state
Lymphocytic phlebitis
Portal hypertension
Pancreatitis

Major vascular occlusion
Mesenteric artery thrombosis
Cholesterol emboli
Colectomy with IMA ligation
Aortic dissection
Aortic reconstruction

Small vessel disease
Diabetes
Vasculitis
Polyarteritis nodosa
Lupus erythematosus
Takayasu arteritis
Granulomatosis with polyangiitis (Wegener's)
Anticentromere antibodies
Buerger's disease
Antiphospholipid antibodies
Amyloidosis
Rheumatoid arthritis
Radiation

Shock
Cardiac failure
Hemodialysis
Pancreatitis
Anaphylaxis

Mechanical obstruction
Strangulated hernia
Colon cancer
Adhesion
Rectal prolapse
Fecal impaction or pseudo-obstruction

Iatrogenic
Surgical
Aortoiliac reconstruction
Cardiopulmonary bypass
Renal transplant
Colonoscopy
Barium enema
Others
Long-distance running
Dialysis
Neurogenic
Spontaneous in young adults
Infections (COVID-19, CMV, *Escherichia coli* O157:H7)
Airplane flight

Risk Factors

Table 1 Drugs potentially associated with ischemic colitis

- Digoxin
- Aspirin
- Naratriptan
- Ma huang (herbal food supplement)
- Phentermine (weight loss medication)
- Oral contraceptives
- Pseudoephedrine
- Phenobarbital
- Nasal decongestants
- Dextroamphetamine
- Type I interferons (IFN-α and IFN-β)
- Tumor necrosis factor α
- Antipsychotics
  - Clozapine
- Serotonergic medications
  - Alosetron
  - Tegaserod
- Vasopressors
- Cocaine
- Methamphetamine

Ischemic Colitis

James F. FitzGerald, MD, FACS, FASCRS[1] Luis O. Hernandez III, MD[1]

Moderate evidence	
Constipation-inducing drugs	Opioid non-opioid
Immunomodulator drugs	Anti TNF IFNα IFNβ
Illicit drugs	Amphetamines Cocaine

Low evidence
Antibiotics
Appetite suppressants
Chemotherapeutic drugs
Decongestants
Diuretics
Ergot alkaloids (often combined with caffeine)
Hormonal therapies
Laxatives
Psychotropic drugs
Serotoninergic drugs

Very low evidence
Digitalis
Kayexalate
NO-Xplode
NSAIDs
Statins
Vasopressors

ACG guideline

Risk Factors

Table 1 Etiologic pathology of ischemic colitis (IC).

Occlusive IC		Non-occlusive IC	
Infarction (arterial ischemia)	Threatened infarction (venous congestion with ischemia)	Colonic low-flow state	
Arteriography	Thrombosis of the mesenterico-portal venous axis	Shock	Hypovolemia, anaphylaxis, septic shock
Infra-renal aortic surgery with sacrifice of the inferior mesenteric artery (IMA)	Portal hypertension	Surgery with cardio-pulmonary bypass, ECPB	
Systemic vasculitis (lupus, polyarteritis nodosa, Takayasu's, disease, thrombo-angiitis obliterans [Buerger's disease])	Mesenteric thrombophlebitis	Vasoactive medications, pressors	Digitalis, diuretics, NSAID medications, stimulant laxatives, estrogens, neuroleptic medications, catecholamines, anti-motility medications
Diabetic angiopathy	Acute pancreatitis	Hemodialysis	
Amyloid angiopathy	Thrombophilia	Obstruction	Occluding tumor, Ogilvie's syndrome (pseudo-obstruction)
Radiation vasculitis		Other	Cocaine use, long-distance runners
Thrombophilias (Protein C or Protein S deficiency, Factor III [anti-thrombin deficiency])			
Infections (Cytomegalovirus, *Escherichia Coli* O157:H7)			

COLON ANATOMY AND PATHOPHYSIOLOGY

It is important to have a clear knowledge of the vascular supply and venous drainage of the intestine to understand the pathophysiology of ISBODI.

Small intestine and large intestine derive their blood supply mainly from the superior mesenteric artery (SMA) and the inferior mesenteric artery (IMA)

COLON ANATOMY AND PATHOPHYSIOLOGY

Blood supply of the colon

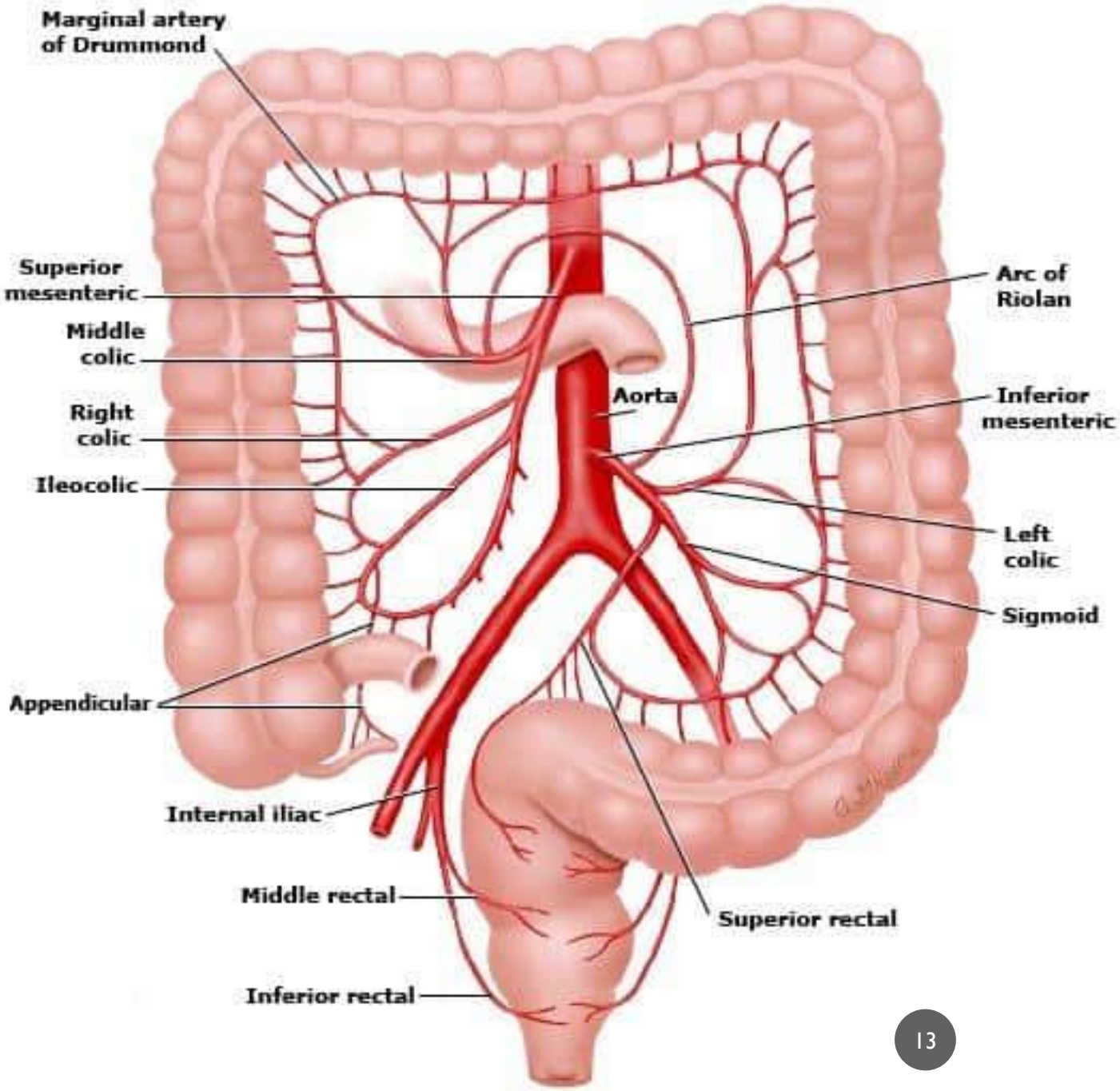

COLON ANATOMY AND PATHOPHYSIOLOGY

The **SMA** arises approximately 1 cm below the celiac artery and runs inferiorly toward the cecum

Middle colic artery arises from the proximal SMA and supplies blood to the proximal to mid transverse colon.

Right colic artery supplies blood to the mid-distal ascending colon. The right colic artery is absent in 13% of individuals.

Ileocolic artery supplies blood to the distal ileum, cecum, and proximal ascending colon.

The **IMA** arises approximately 6 to 7 cm below the SMA. The IMA gives rise to the **left colic artery** and **sigmoid arteries** continuing as the superior rectal (hemorrhoidal) artery. It is largely responsible for supplying blood distal to the transverse colon.

COLON ANATOMY AND PATHOPHYSIOLOGY

Blood supply of the colon

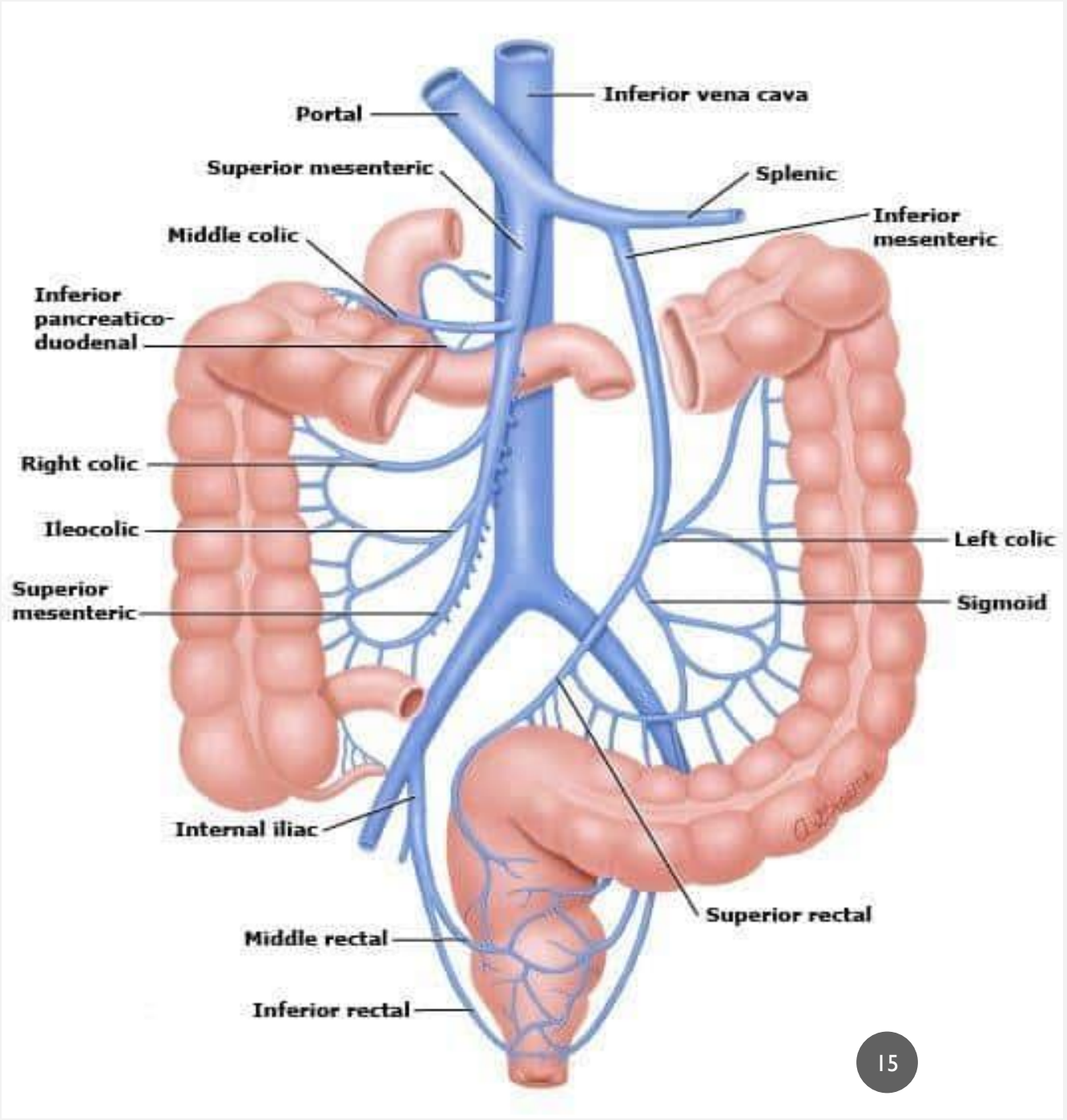

COLON ANATOMY AND PATHOPHYSIOLOGY

Blood supply of the colon

The mesenteric veins parallel their corresponding arteries.

The **SMV** drains the small intestine, cecum, and ascending and transverse colon via the jejunal, ileal, ileocolic, right colic, and middle colic veins.

The **IMV** drains the descending colon through the left colic, the sigmoid through the sigmoid vein, and the rectum through the superior rectal vein.

The IMV fuses with the splenic vein, which then joins the SMV to form the portal vein.

COLON ANATOMY AND PATHOPHYSIOLOGY

Blood supply of the colon

There are 3 watershed zones in the colon that receives blood supply from the distal branches of two large arteries. As they have the fewest vascular collaterals, they are prone to develop non-occlusive IC when blood flow decreases.

The watershed zones include:

- **Splenic flexure or Griffith's point**
- **Rectosigmoid region or Sudeck's point**
- **Ileocecal region**

- ***Isolated right colon*** ischemia can occur in about 10% of cases. Right colonic involvement generally occurs in patients with chronic renal failure requiring hemodialysis and Coronary artery disease and atrial fibrillation and is associated with severe IC

COLON ANATOMY AND PATHOPHYSIOLOGY

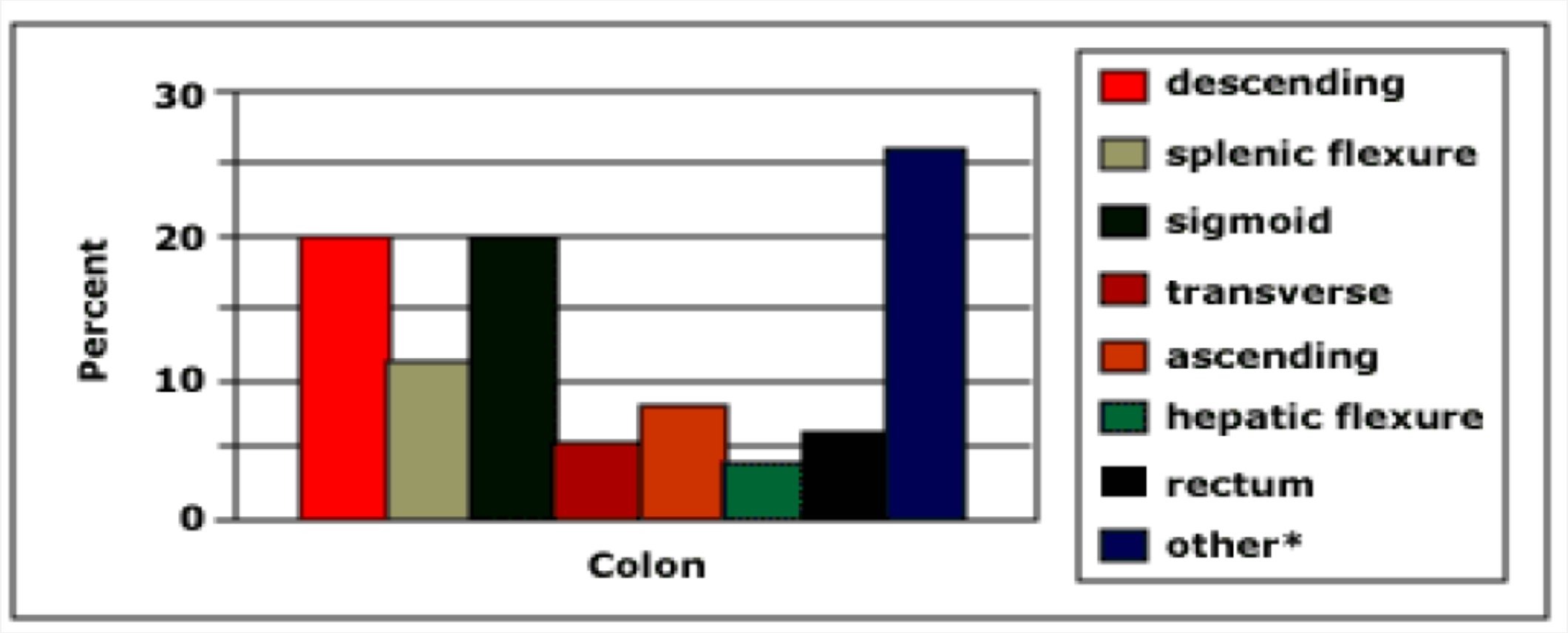

* Other areas refer to combination of different regions.

COLON ANATOMY AND PATHOPHYSIOLOGY

Table 4. Segmental distribution of colon ischemia (CI)

Brandt *et al.* (7)		**Longstreth and Yao (9)**		**Montoro e*t al.* (17)**		**Yadav *et al.* (10)**	
Number of patients	313	Number of patients	417	Number of patients	364	Number of patients	445
Segment		*Segment*		*Segment*		*Segment*	
Left colon pattern	32.6%	Left side	87.0%	Sigmoid colon	69.5%	Descending colon	56.0%
Distal colon pattern	24.6%	Right side	9.0%	Descending colon	58.0%	Sigmoid colon	45.0%
Right colon pattern	25.2%	Bilateral with transverse	2.0%	Transverse colon	22.9%	Transverse colon	39.0%
Transverse colon pattern	10.2%	Transverse only	1.0%	Rectum	15.0%	Cecum/ascending colon	24.0%
Pancolonic pattern	7.3%	Rectum only	<1.0%	Ascending colon	10.0%	Rectum	15.0%
				Hepatic flexure	10.0%		
				Cecum	6.5%		
				Entire colon	2.8%		

ACG

COLON ANATOMY AND PATHOPHYSIOLOGY

Etiology of hypoperfusion

There are several physiological factors which can make the colon more susceptible to ischemia:

1. **less blood flow to the colon** (*per* 100 g of tissue) as compared to other parts of the GI tract.

2. Functional colonic **motor activity further decreases colonic blood flow**.

3. The colon also depends on **collateral circulation** frequently. During hypotensive episodes, the colon cannot autoregulate well compared with the rest of the gastrointestinal tract

4. colonic mucosa is less easily damaged by ischemia but once destroyed, **slow recovery** occurs

COLON ANATOMY AND PATHOPHYSIOLOGY

Etiology of hypoperfusion

- **Nonocclusive colonic ischemia:**
  - In **95% of cases**, CI occurs due to **sudden but transient reduction in blood flow** to the colon due to non-occlusive causes and as a result, the watershed zones are affected.
  - *The **rectum** was involved in only **5%** of patients*.

Most of the time, the cause of non-occlusive ischemia remains **unidentified**:

- Type I: due to localized non-occlusive ischemia secondary to **small-vessel disease**
- Type II: Rarely, episodes of non-occlusive ischemia secondary to **systemic** hypotension decreased cardiac output or aortic surgery are identified

COLON ANATOMY AND PATHOPHYSIOLOGY

Etiology of hypoperfusion

- **Occlusive ischemia**

  - **Embolic and thrombotic arterial occlusion**: due to spontaneous emboli from a proximal source to the mesenteric vessels, or iatrogenically from aortic instrumentation, rarely have colonic ischemia without concomitant small bowel ischemia

  - **Mesenteric vein thrombosis**: Mesenteric vein thrombosis rarely affects the colon; when present, it almost always affects the distal small intestine/proximal colon

Phlebosclerotic colitis is a rare form of ischemic colitis that results from venous obstruction caused by fibrotic sclerosis and calcification of the walls of the mesenteric veins

COLON ANATOMY AND PATHOPHYSIOLOGY

Etiology of hypoperfusion

Uncertain role of hypercoagulability

Other factors must be involved in precipitating an ischemic event (a **"two-hit" hypothesis**)

It is also possible that specific types of thrombophilic disorders may predispose to particular forms of colonic ischemia, such as chronic ischemic colitis and stricture formation.

one report from Greece: prevalence of antiphospholipid and Factor V Leiden mutations

Clinical Features

- CI is mostly a **benign and self-limiting** disease in most of the time
- Most of the patients with non-iatrogenic causes are **older than 60 years** old with a slight **female** predilection.
- Rarely, IC can also occur in **young** individuals due to substance abuse, vasculitis, long distance running, thrombophilia, sickle cell crisis with microvascular occlusion.
- One study found that **6.8% of patients had a recurrence of CI** with a mean follow-up of 4.5 years and is more common in patients with hereditary thrombophilia (deficiencies of protein C, protein S, antithrombin III, and factor V Leiden mutation), anti-phospholipid syndrome, active smoking, abdominal aortic aneurysm, coronary artery disease and elevated serum creatinine

Clinical Features

Acute colonic ischemia

Symptoms and signs

Rapid onset of mild cramping abdominal pain and tenderness over LLQ or hypogastrium, and **urgency to defecate** followed by **hematochezia within 24 h**.

The **bleeding is not severe** enough to require blood transfusion.

Patients with ***right colon ischemia*** usually present with hypogastric pain rather than hematochezia.

Physical examination may reveal **mild to moderate tenderness** over the LLQ or over the involved segment

Gangrenous colitis or fulminant pancolitis is generally recognized by marked abdominal tenderness, rebound tenderness, hypotension or shock.

Clinical Features

Acute colonic ischemia

Symptoms and signs

Three progressive clinical stages have been described:

- **Hyperactive phase:** Soon after occlusion or hypoperfusion, patient feels abdominal pain because of bowel ischemia and hyperperistalsis with frequent passage of bloody, loose stools.
- **Paralytic phase** (after 3 to 6 h): patient feels better as the intestine becomes aperistaltic and the intramural pain receptors become damaged by ischemia. The abdomen becomes more tender and distended without bowel sounds.
- **Shock phase:** Massive fluid, protein, and electrolytes start to leak through a damaged, gangrenous mucosa. Severe dehydration with shock and metabolic acidosis may develop, requiring rapid surgical intervention.

Clinical Features

Acute colonic ischemia

Laboratory studies

- ✓ There are no specific laboratory markers for ischemia
- ✓ Increased serum lactate, LDH, CPK, or amylase may indicate colonic infarction.
- ✓ Decreased hemoglobin levels may reflect intestinal blood loss.
- ✓ WBC above 20,000 and metabolic acidosis in a patient with signs and symptoms of colonic ischemia is highly suggestive of intestinal ischemia with infarction.
- ✓ Albumin levels below 2.8 g/dL were more common in those with gangrenous changes.

Clinical Features

Chronic ischemic colitis

Patients with episodes of chronic recurrent colonic ischemia can present with recurrent abdominal pain, bloody diarrhea, weight loss from protein-losing enteropathy, recurrent bacteremia, persistent sepsis, or symptomatic colonic strictures.

Approximately 20 percent of patients with recurrent ischemia develop chronic ischemic colitis.

Chronic ischemia may develop into segmental ulcerating colitis or strictures, typically apparent within three to six months that were diagnosed with colonoscopy.

Clinical Features

Chronic ischemic colitis

Ischemic strictures

that produce no symptoms should be observed. Some strictures will resolve in 12-24 months without specific therapy.

If **symptoms** of partial obstruction develop, **segmental resection** is indicated.

Endoscopic dilation or stenting may be an alternative for patients who are poor surgical candidates. However, the efficacy of this approach has not been

Clinical Features

Chronic ischemic colitis

Chronic ischemic colitis can occur in **long-distance runners** and presents with pain in the lower abdomen, diarrhea, and mild bleeding. Treatment with rehydration and correction of metabolic abnormalities is usually sufficient

Phlebosclerotic colitis is a rare form of ischemic colitis that results from venous obstruction caused by fibrotic sclerosis and calcification of the walls of the mesenteric veins. It usually involves the right colon. Linear calcifications in the region of the right colon can be seen on plain abdominal radiographs, while computed tomography (CT) scans may reveal colonic wall thickening associated with mesenteric venous calcifications. Symptoms usually resolve spontaneously.

Clinical Features

Recurrent ischemic colitis

Recurrence of CI is said to occur when a patient has one discrete episode that resolves and the patient subsequently re-presents with similar symptoms and has another independent diagnosis of CI.

When comparing recurrent CI with nonrecurrent CI, an abdominal aortic aneurysm (40.0% vs. 4.7%, P <0.01) and active smoking (50.0% vs. 18.7%, P <0.05) were more common in the recurrent cohort

Evaluation for thrombophilia should be considered in young patients with CI and all patients with recurrent CI

Diagnosis

- The diagnosis of colonic ischemia is usually suspected based on such **history**, together with **physical examination** and clinical setting. It is confirmed with **imaging**, when possible, typically with CT of the abdomen.

- In one review, the presence of four or more risk factors (**older than 60, hemodialysis, hypertension, hypoalbuminemia, diabetes mellitus, constipation-inducing medications**) was 100 percent predictive of colonic ischemia.

- For patients who present with **fulminant gangrenous** colonic ischemia with peritonitis and/or colon perforation, a definitive diagnosis will necessarily be made in the **operating room**.

Diagnosis

Laboratory studies

There are no specific laboratory markers for ischemia

Laboratory testing should be considered to help **predict CI severity**

Table 5. Recommended initial serology and stool studies for suspected colon ischemia (CI)

Blood tests
Albumin
Amylase
Complete blood count
Comprehensive electrolyte panel
Creatine kinase (CK)
Lactate
Lactate dehydrogenase (LDH)
Stool tests
Clostridium difficile toxin assay
Culture
Ova and parasite

Diagnosis

Abdominal imaging

Plain X-ray abdomen is normal in most of the time

Rarely it may show '**thumbprinting**' due to submucosal edema/hemorrhage, pneumatosis linearis due to necrosis of the colon wall, portal venous gas, colonic ileus or pneumoperitoneum due to perforation.

When plain radiographic findings suggest ischemia, they may portend a **worse prognosis** compared with those without such findings

DIAGNOSIS







Arrows point to "Thumb printing" defects along the margin of the colon characterstic of ischemic colon. The normal haustra become thickened at regular intervals appearing like thumbprints projecting into the aerated lumen

Diagnosis

Abdominal imaging

CT of the abdomen with intravenous & Oral contrast is typically the **first image**.
CT findings are nonspecific and can initially be normal.

- Edema and thickening of the bowel wall in a segmental pattern (thumbprinting or "target" or "double-halo" appearance from hyperdensity of the mucosa and muscularis).
- Irregular bowel contours
- Mesenteric inflammation with stranding of the fat
- free peritoneal fluid.
- Pneumatosis coli, gas in the mesenteric or portal veins, or pneumoperitoneum indicating perforation may be seen in the more advanced stages
- Major arterial embolic or venous obstruction more consistent with acute mesenteric ischemia (colonic involvement isolated to the right side)

Diagnosis

Abdominal imaging

Multiphasic CTA should be performed on any patient with **suspected IRCI** or in any patient in whom the **possibility of AMI** cannot be excluded

In a patient in whom the presentation of CI may be a heralding sign of AMI (e.g., IRCI, severe pain without bleeding, atrial fibrillation), and the multiphasic CT is negative for vascular occlusive disease, **traditional splanchnic angiography** should be considered for further assessment

Diagnosis

Abdominal imaging

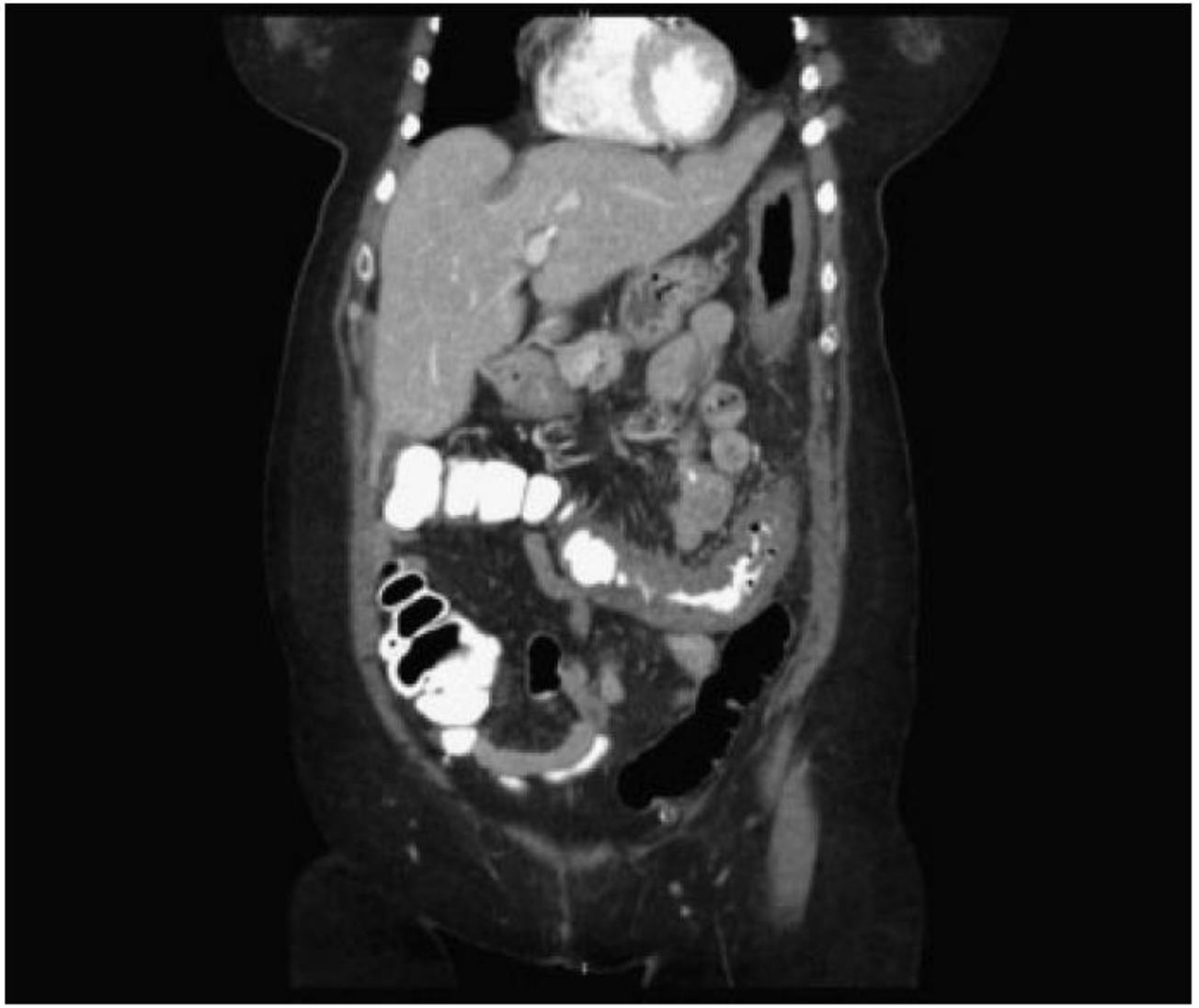

Fig. 2 Computerized tomographic scan of coronal sections of the abdomen showing thickening of the splenic flexure, descending colon, and proximal sigmoid colon in a patient with documented ischemic colitis.


smooth thickening


distal descending colon

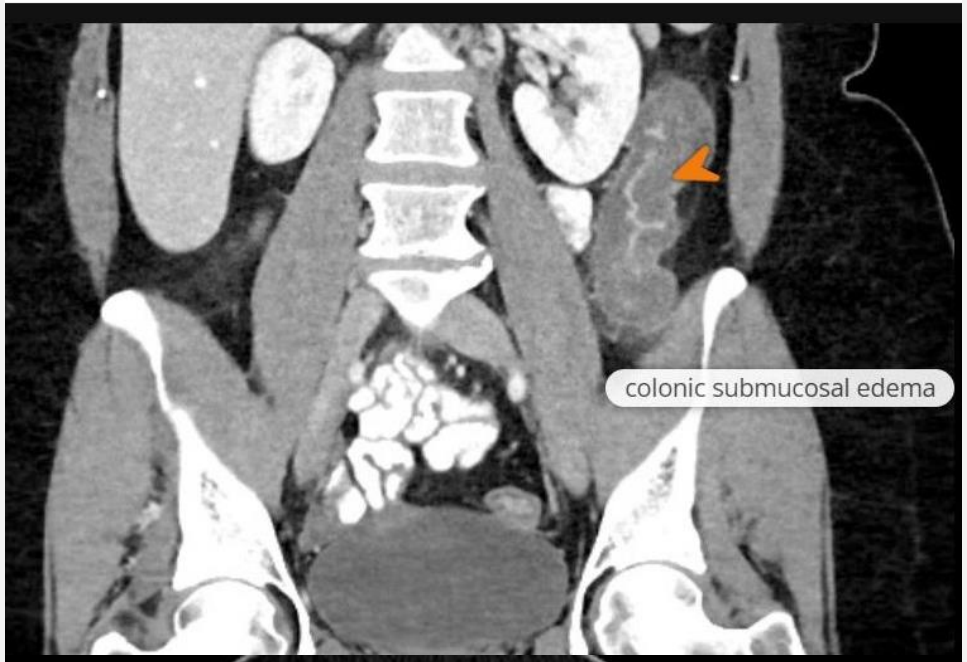
colonic submucosal edema

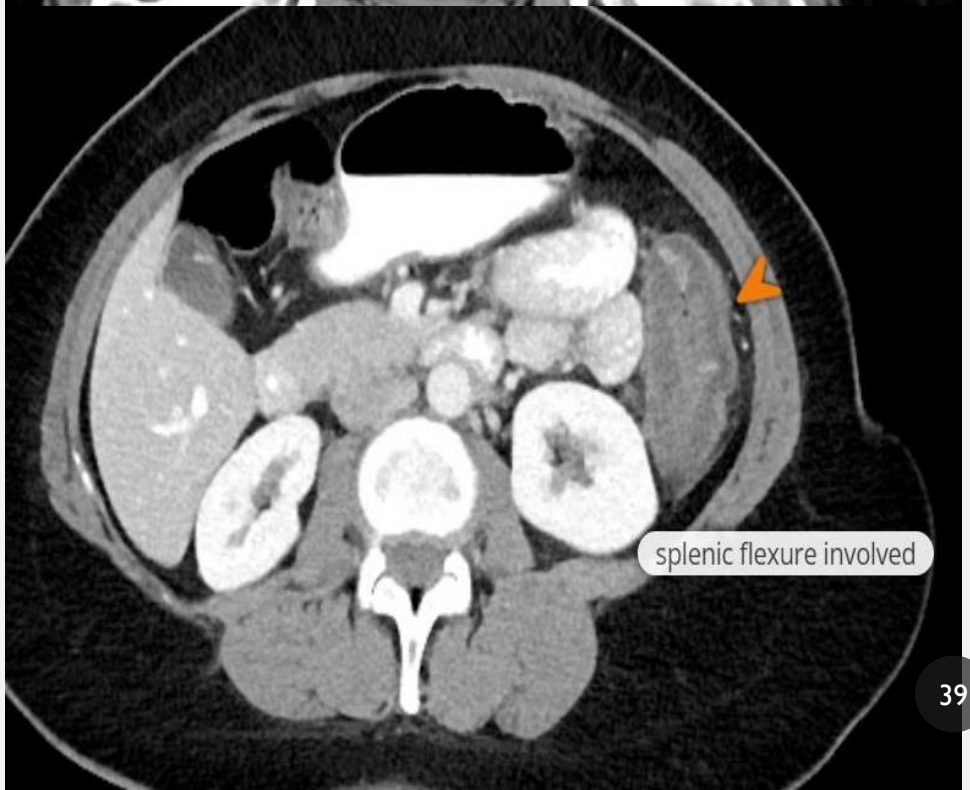
splenic flexure involved

Diagnosis

Abdominal imaging

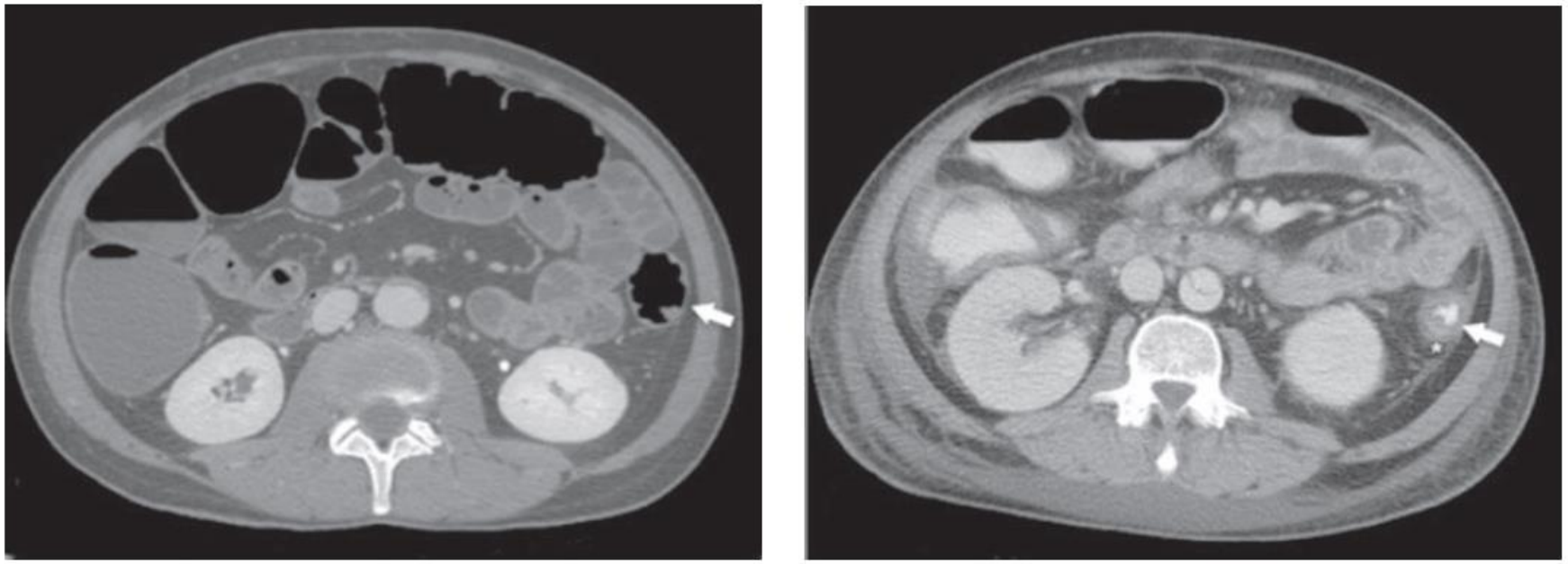

(a) (b)

FIGURE 1: 65-year-old patient with abdominal aortic dissection in acute phase IC caused by NOMI: (a) before reperfusion, colonic wall appears thinned (paper-thin wall) and hypotonic (arrow); (b) after reperfusion, note colonic wall thickening (arrow) and pericolic fluid (star); at endoscopic evaluation (not showed), the colon shows parcelled necrosis confirming the diagnosis of NOMI with reperfusion.

Diagnosis

Abdominal imaging



FIGURE 2: Contrast-enhanced CT in patients with acute occlusive IC: homogeneous left colonic involvement with disappearance of the lumen (arrow) and hyperperfusion of the mucosa in coronal plane. The endoscopy showed the presence of thickened mucosa with hemorrhagic phenomena. The histological findings were represented by increased thickness of the entire mucosal layer with intraparietal edema with hemorrhage and reactive inflammatory cells.

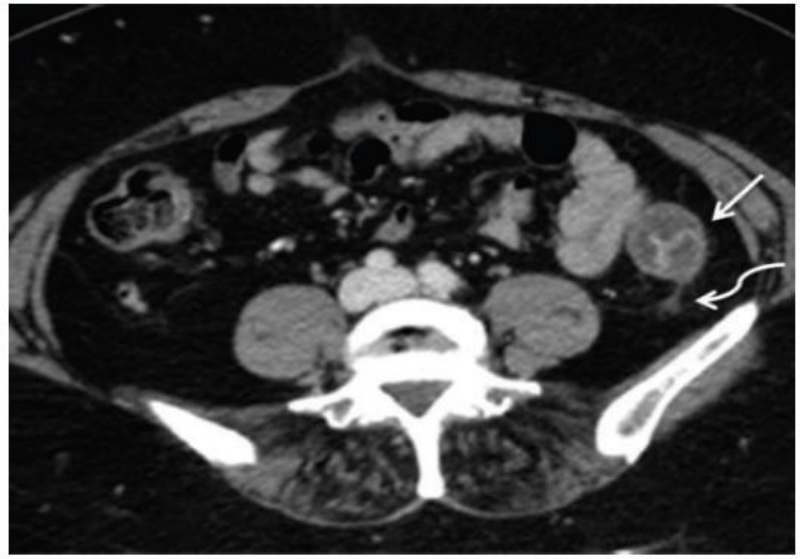

FIGURE 3: Patients with embolic IMA occlusion in acute phase: left colonic wall thickening (white arrow) with evidence of "little rose" sign or target aspect after i.v. contrast medium administration was detected; pericolic fluid was also present (curved arrow); the endoscopy showed edematous and thickened mucosa with diffuse petechial hemorrhage and hemorrhagic nodules; in some segments also hemorrhagic ulcerations were detected. These findings were histologically related to vascular congestion with intraparietal haemorrhage and increased cellularity with the presence of reactive inflammatory cells.

Diagnosis

Abdominal imaging

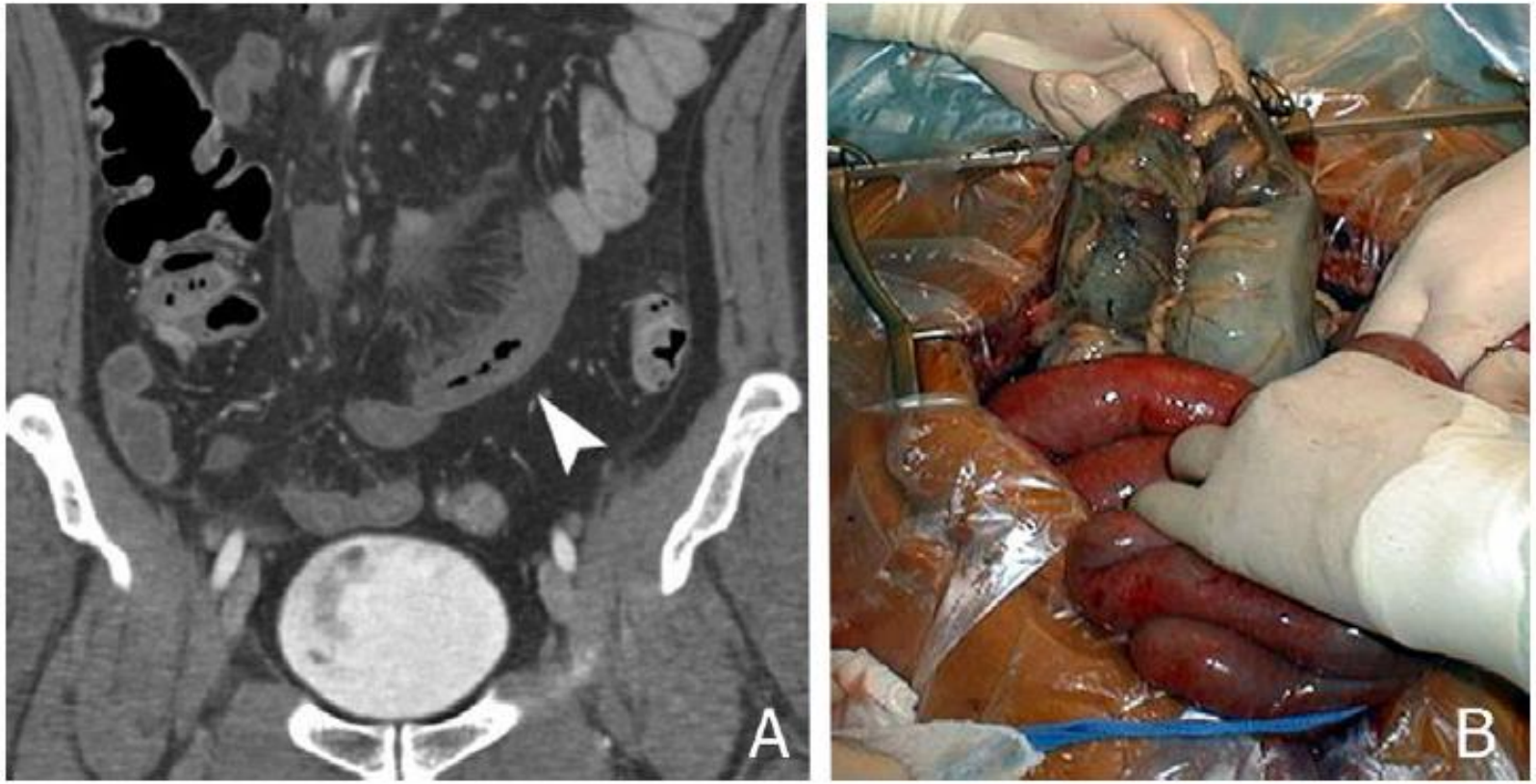

Figure 1. A. CT with coronal reconstruction in a 74-year-old female hospitalized with left lower quadrant abdominal pain and lower GI bleeding and associated multi-organ failure; there is necrosis of the sigmoid colon (lack of enhancement of the bowel wall with contrast injection). B. Intra-operative appearance of transmural ischemic necrosis of the transverse colon.

Diagnosis

Lower endoscopy

- **Colonoscopy with biopsy within 48 h is the next step to confirm the diagnosis of CI.**
- Colonoscopy should not be performed in patients with **acute peritonitis** on physical examination or on imaging.
- Should be performed with **minimal air insufflation** to avoid excessive distention and **CO2** appears to be the best insufflating agent to use in patients with CI and should be used whenever available.
- colonoscope should be passed only to **the distal-most aspect of the affected region.**
- **Biopsies** of the colonic mucosa should be obtained except in cases of gangrene

Diagnosis

Lower endoscopy

Colonoscopic findings in the acute setting frequently include

- ❑ In non-gangrenous IC
  - A single linear ulcer running along the longitudinal axis of the colon (the "single-stripe sign")
  - edematous, friable mucosa, erythema, and interspersed pale areas
  - Bluish hemorrhagic nodules may be seen representing submucosal bleeding; these are the equivalent of "thumbprints“
  - scattered petechial hemorrhages with pale areas
  - Occasional patients have pseudomembranous colitis with yellowish round plaques or confluent membranes not related to C. difficile infection.

- ❑ In gangrenous IC
  - colon mucosa will appear as black or gray-green

- Ischemia rather than inflammatory bowel disease is suggested by segmental distribution, abrupt transition between injured and non injured mucosa, and rectal sparing.

Diagnosis

Lower endoscopy

Table 2	Favier endoscopic classification of IC [46].
Stage 1	Ischemia limited to the mucosa with petechiae and small ulcerations with intervening healthy mucosa
Stage 2	Ischemia extending to the muscularis mucosa with large ulcerations
Stage 3	Transmural ischemia with necrosis of the muscularis and possible perforation

Diagnosis

Lower endoscopy

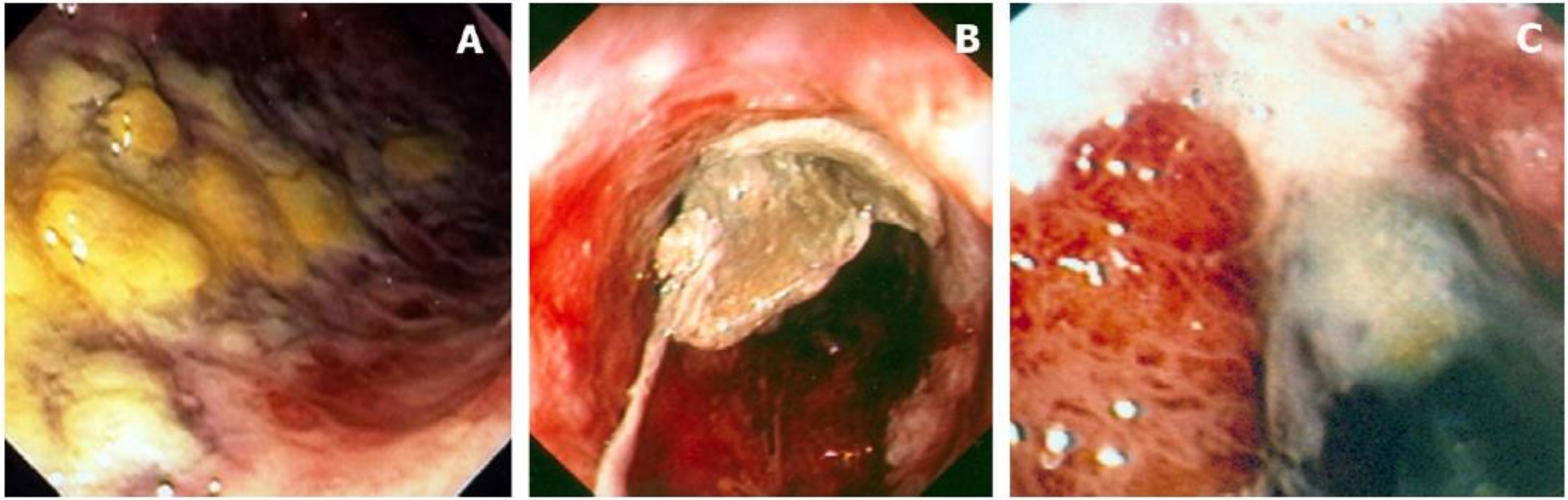

Figure 2. Endoscopic appearance of various stages of ischemic colitis according to the Favier classification: A. Stage 1. B. Stage 2. C. Stage 3. (Reproduced with the kind authorization of Dr. X. Treton and Professor Y. Bouhnik).

ELSEVIER

Endoscopic Spectrum of Ischemic Colitis



K Mönkemüller and CM Wilcox,
University of Alabama, Birmingham,
Alabama, USA

2012 Elsevier. All Rights Reserved

Diagnosis

Lower endoscopy



The ***colon single-stripe sign (CSSS)*** is a highly specific sign of CI described by Zuckerman in 2003.
CSSS is defined as a single inflammatory band of erythema with erosion and/or ulceration along the longitudinal axis of the colon;
all CSSSs in the study of Zuckerman were >5 cm in length and 89% of CSSSs were found in the left colon.

Diagnosis

Lower endoscopy



"Colon Stripe" sign
Longitudinal ulcer along watershed area

"Colon Stripe" sign





Mucosal Edema
Friability
Petechial Hemorrhage

Diagnosis

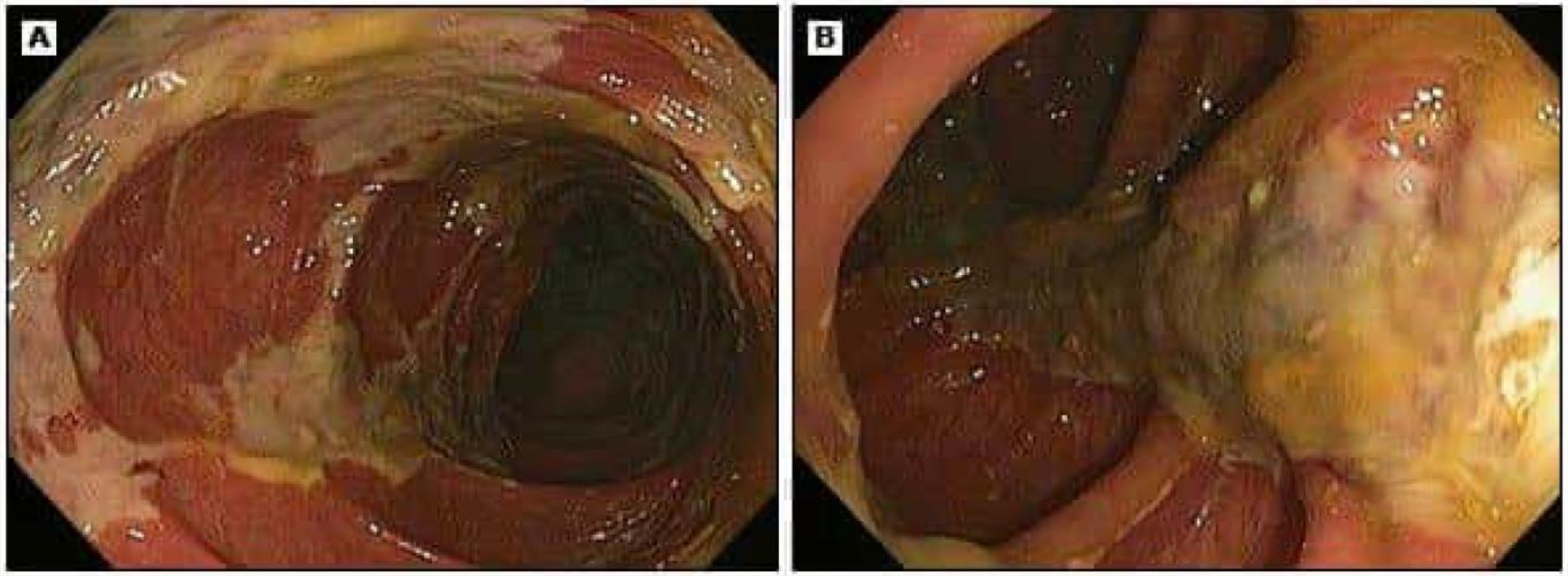

Colonoscopy in a patient with ischemic colitis reveals long shallow ulcers in the descending colon and splenic flexure

Diagnosis

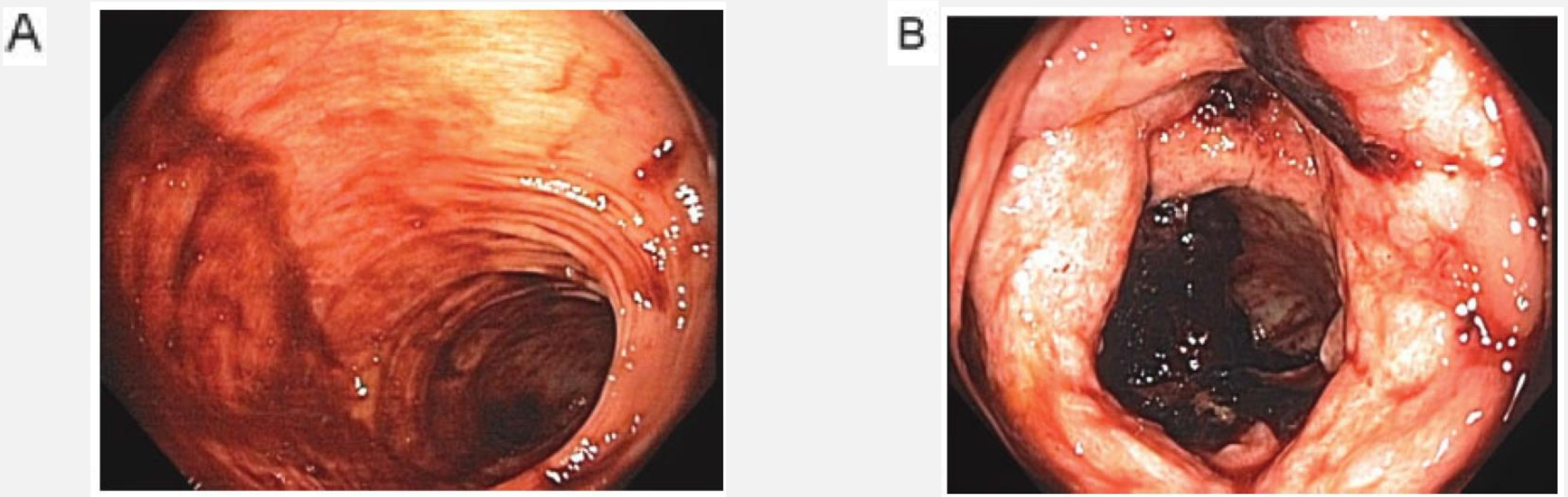

Fig. 3 Endoscopic photograph of colonic mucosa demonstrating: (A) mucosal bleeding, erythema, and intraluminal blood consistent with mild ischemic colitis; (B) ulceration, scattered erosions, and intraluminal clot consistent with severe colonic ischemia.

Diagnosis

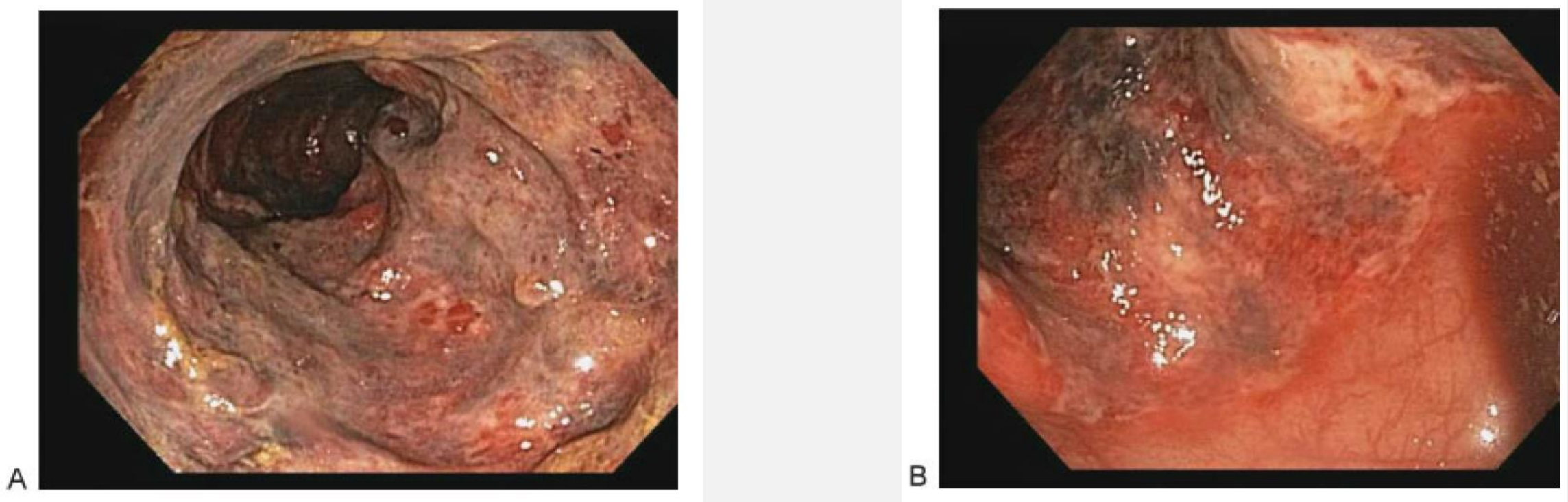

Fig. 4 Photograph from colonoscopy which demonstrates: (A) gangrenous mucosa and (B) a transition point, distally, to normal mucosa.

Diagnosis

- Biopsies taken from affected areas may show nonspecific changes such as hemorrhage, crypt destruction, capillary thrombosis, granulation tissue with crypt abscesses, and pseudopolyps, which may mimic **Crohn** disease.

- In the chronic phase of ischemic colitis, mucosal atrophy and areas of granulation tissue may be found.

- Biopsy of a postischemic stricture is marked by extensive transmural fibrosis and mucosal atrophy.

Diagnosis

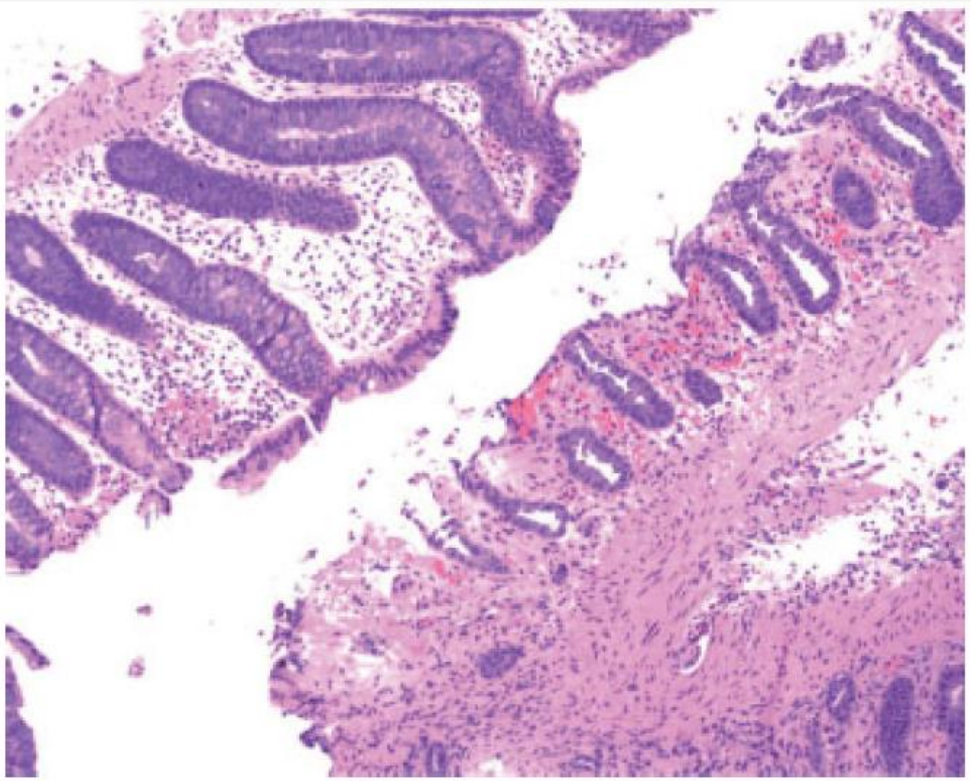

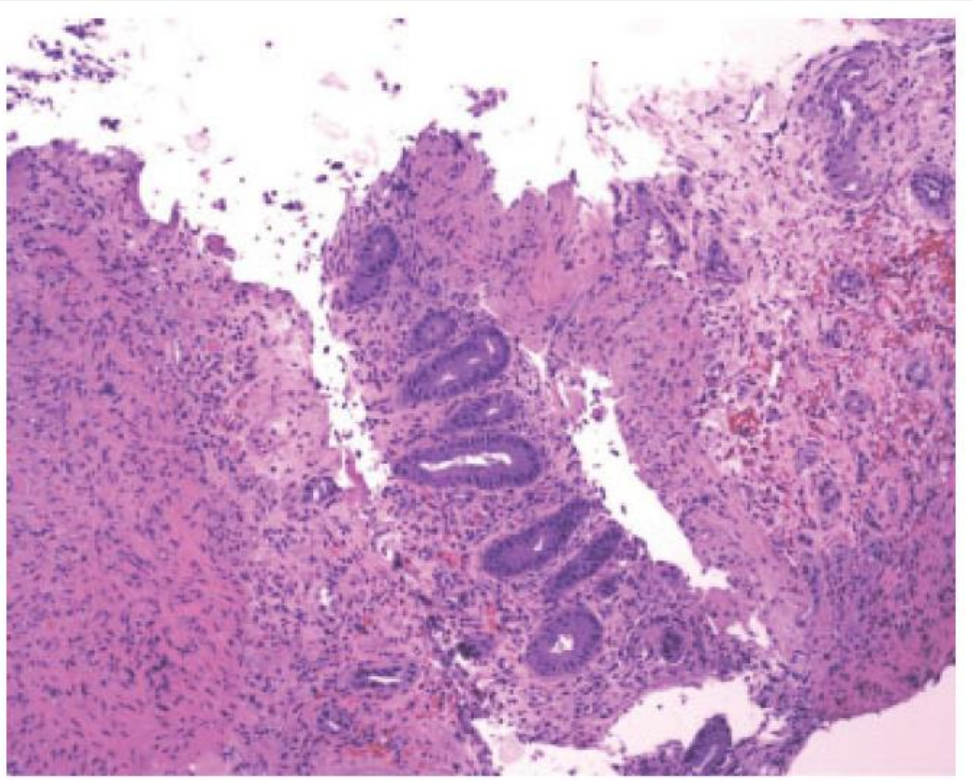

Fig. 5 Histologic photograph from a biopsy specimen of a patient with ischemic colitis which shows ulceration with fibrinous exudate, vascular congestion, and hemorrhage with associated acute inflammation and granulation tissue reaction.

Differential Diagnosis

The differential diagnosis of colonic ischemia also includes infectious colitis, inflammatory bowel disease, diverticulitis, radiation enteritis, solitary rectal ulcer

C. difficile infection should be excluded in hospitalized patients exposed to antibiotics. This infection produces marked thickening of the colon on CT scans, as well as very high total white blood cell counts, which resemble the findings of ischemic colitis. Although occult blood may be detected in diarrheal stools of symptomatic patients, grossly bloody stools are quite rare in C. difficile infection.

Differential Diagnosis

Large versus small bowel ischemia

Acute small bowel ischemia	Acute colonic ischemia
Age varies with etiology of ischemia	90 percent of patients over age 60 years
Acute precipitating cause is typical	Acute precipitating cause is rare
Patients appear severely ill	Patients do not appear severely ill
Pain is usually severe, tenderness is not prominent early	Mild abdominal pain, tenderness present
Bleeding uncommon until very late	Rectal bleeding, bloody diarrhea typical
MRA or MDCT angiography may be considered as the initial diagnostic test; angiography is recommended if there is strong clinical suspicion	Colonoscopy is procedure of choice

Treatment

Treatment of acute colonic ischemia depends upon its **etiology**, **severity**, and the **clinical setting**. Most patients with colonic ischemia will resolve with **supportive care**

risk factors associated with a **poor outcome** include:

- male sex
- hypotension (systolic blood pressure <90 mmHg)
- tachycardia (heart rate >100 beats/minute)
- abdominal pain without rectal bleeding
- BUN >20 mg/dL
- hemoglobin <12 g/dL
- LDH >350 units/L
- serum sodium <136 mEq/L
- WBC >15,000 cells/microliter

Table 7. **Predictors of disease severity: factors from multiple studies that are significantly associated with the requirement for surgery and/or mortality**

Epidemiologic factors	*Vital signs*
Antibiotic treatment	Pulse >100 beats/min
Chronic obstructive pulmonary disease	
Chronic kidney disease	Pulse >90 beats/min
Hepatitis C positivity	Systolic blood pressure <90 mm Hg
History of cancer	*Serology*
Male gender	Hemoglobin <12 mg/dl
Warfarin use	Na <136 mEq/l (mmol/l)
Presentation of disease	LDH >450 U/l
Abdominal pain without rectal bleeding	BUN >28.0 mg/dl
Nonbloody diarrhea	*Colonoscopic finding*
Peritoneal signs	Ulceration
	Distribution of disease
	Bilateral or right-side disease distribution
	Isolated right colon involvement

Treatment

Table 3 Risk factors for poor prognosis in patients with ischemic colitis.

Epidemiology and past history
Male gender
Collagen vascular disease
Chronic renal insufficiency, dialysis
Chronic constipation
Cardiovascular risk factors or past history
Other (cancer, COPD, hyperthyroidism)
Clinical
Lack of lower GI bleeding
Signs of peritoneal irritation
Multi-organ failure, shock
Right colon involvement
Involvement of the entire colon
Laboratory findings
Anemia, hyponatremia
Hypoproteinemia
Leukocytosis
Hyperlactacidemia > 2.5 mM/l
Radiologic
Pneumatosis intestinalis, portal venous air, pneumoperitoneum (CT scan)
Loss of arterial flow in muscularis (Doppler US)
Endoscopic
Depth of ischemia (Favier classification)
Necrosis, perforation
Circumferential ulceration

COPD: chronic obstructive pulmonary disease.

Table 6. Classification of disease severity and management

Disease severity	Criteria	Treatment
Mild	Typical symptoms of CI with a segmental colitis not isolated to the right colon and with none of the commonly associated risk factors for poorer outcome that are seen in moderate disease	Observation Supportive care
Moderate	Any patient with CI and up to three of the following factors:	Correction of cardiovascular abnormalities (e.g., volume replacement) Broad-spectrum antibiotic therapy Surgical consultation
	Male gender	
	Hypotension (systolic blood pressure <90 mm Hg)	
	Tachycardia (heart rate >100 beats/min)	
	Abdominal pain without rectal bleeding	
	BUN >20 mg/dl	
	Hgb <12 g/dl	
	LDH >350 U/l	
	Serum sodium <136 mEq/l (mmol/l)	
	WBC >15 cells/cmm ($\times 10^9$/l)	
	Colonic mucosal ulceration identified colonoscopically	
Severe	Any patient with CI and more than three of the criteria for moderate disease or any of the following:	Emergent surgical consultation (treatment is likely to be surgical) Transfer to intensive care unit Correction of cardiovascular abnormalities (e.g., volume replacement) Broad-spectrum antibiotic therapy
	Peritoneal signs on physical examination	
	Pneumatosis or portal venous gas on radiologic imaging	
	Gangrene on colonoscopic examination	
	Pancolonic distribution or IRCI on imaging or colonoscopy	

The ACG 2015 risk stratification

Treatment

The ACG 2015 risk stratification

Mild colonic ischemia – Suspected colonic ischemia based upon typical symptoms and advanced abdominal imaging or lower endoscopy consistent with colonic ischemia but with **no risk factors** associated with a poor outcome. **The patient has no clinical signs that would indicate the need for immediate exploration.**

Moderate colonic ischemia – Suspected colonic ischemia based upon typical symptoms and advanced abdominal imaging or lower endoscopy consistent with colonic ischemia and **up to three risk factors** associated with a poor outcome. The **patient has no clinical signs that would indicate the need for immediate exploration.**

Severe colonic ischemia – Suspected colonic ischemia based upon typical symptoms and **more than three** of the criteria for moderate disease or any of the following: peritoneal signs on physical examination. **Emergent surgical consultation and Transfer to ICU should be done**

pneumoperitoneum

Pneumatosis

portal venous gas on radiologic imaging

gangrene on colonoscopic examination.

Treatment

*pneumoperitoneum, pneumatosis, or portal venous gas on radiologic imaging; gangrene on colonoscopic examination; pancolonic ischemia or colon involvement

isolated to the right side on imaging by colonoscopy or CT

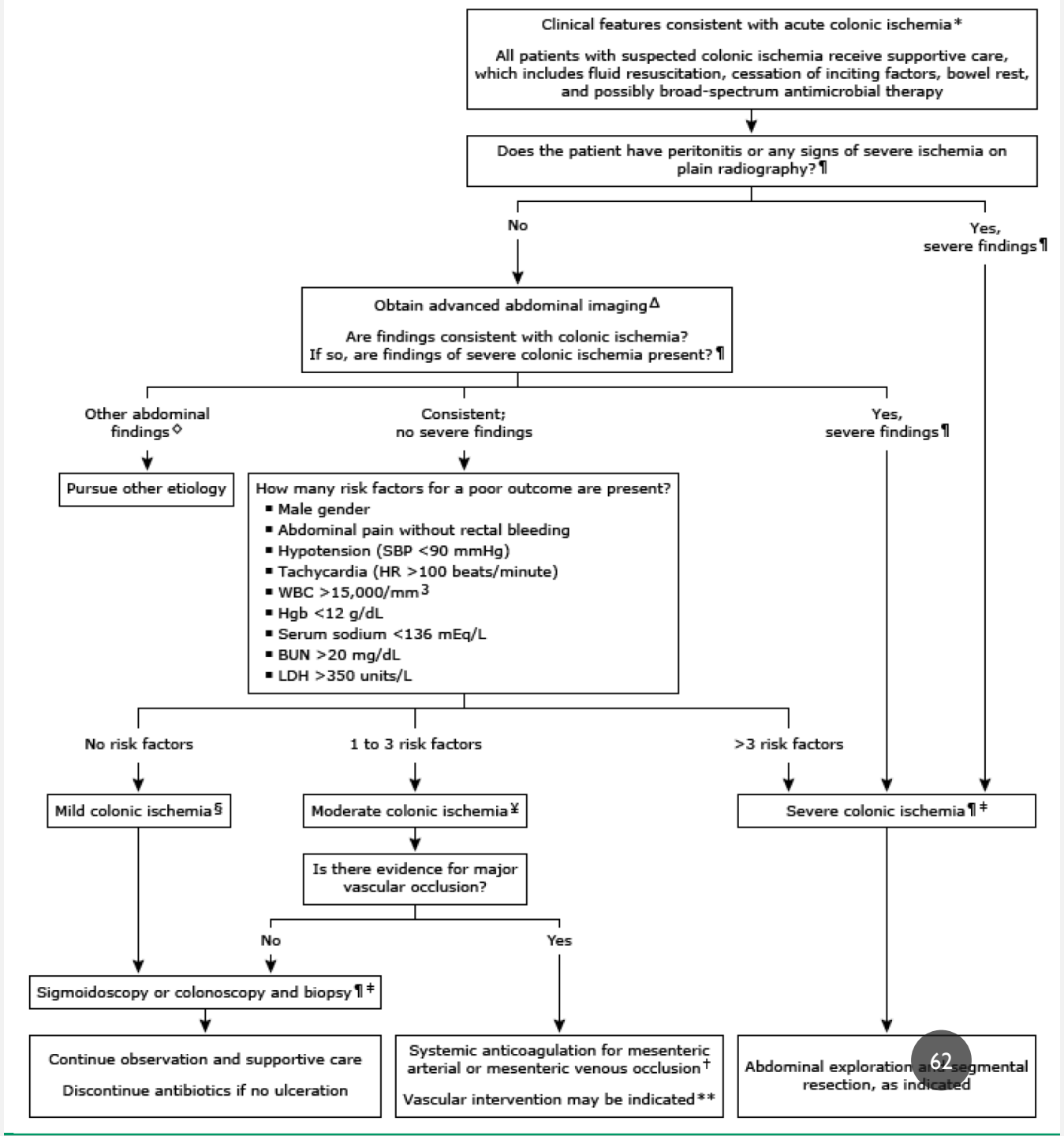

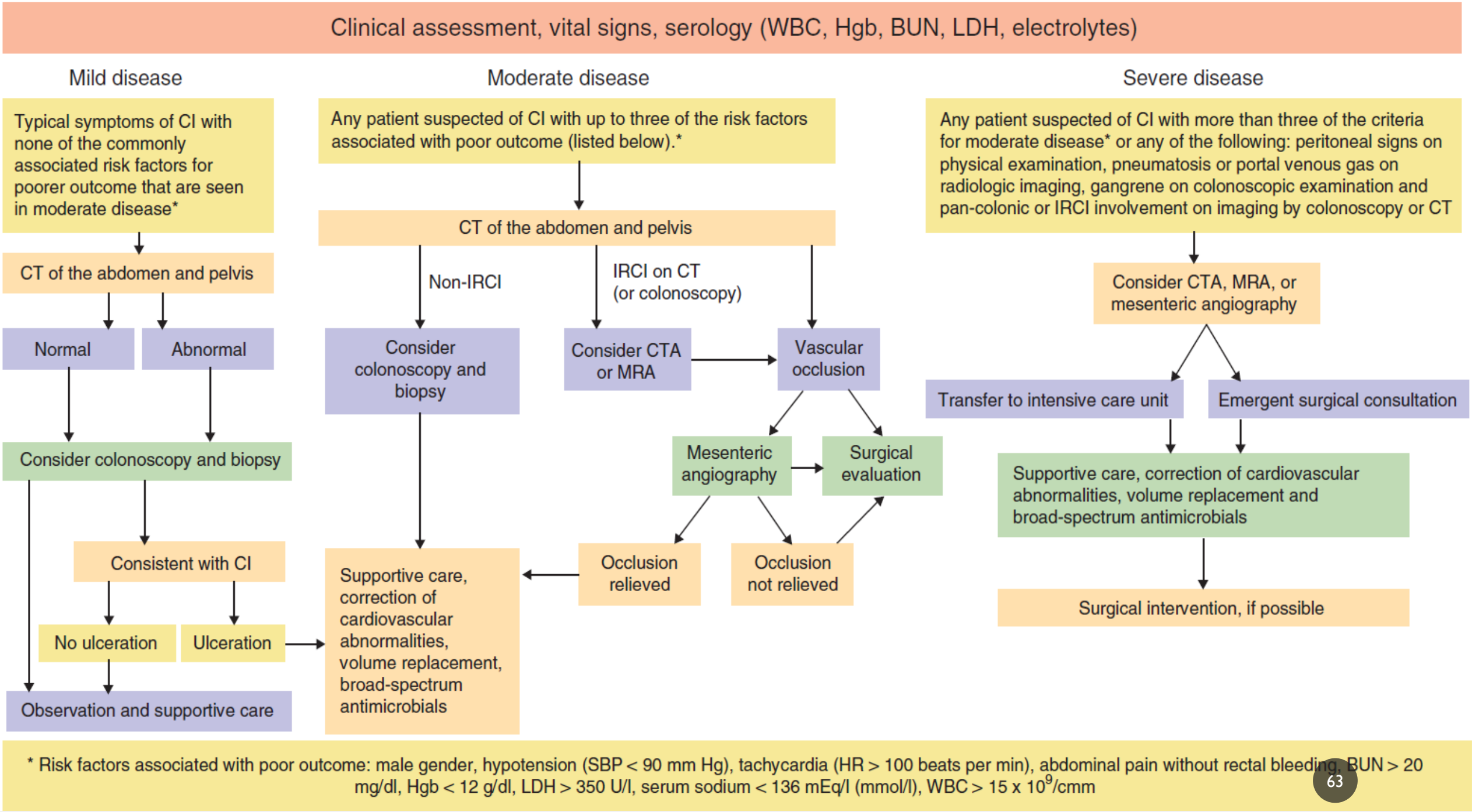
Clinical assessment, vital signs, serology (WBC, Hgb, BUN, LDH, electrolytes)
Mild disease
Typical symptoms of CI with none of the commonly associated risk factors for poorer outcome that are seen in moderate disease*
CT of the abdomen and pelvis
Normal
Abnormal
Consider colonoscopy and biopsy
Consistent with CI
No ulceration
Ulceration
Observation and supportive care
Moderate disease
Any patient suspected of CI with up to three of the risk factors associated with poor outcome (listed below).*
CT of the abdomen and pelvis
Non-IRCI
IRCI on CT (or colonoscopy)
Consider colonoscopy and biopsy
Consider CTA or MRA
Vascular occlusion
Mesenteric angiography
Surgical evaluation
Occlusion relieved
Occlusion not relieved
Supportive care, correction of cardiovascular abnormalities, volume replacement, broad-spectrum antimicrobials
Severe disease
Any patient suspected of CI with more than three of the criteria for moderate disease* or any of the following: peritoneal signs on physical examination, pneumatosis or portal venous gas on radiologic imaging, gangrene on colonoscopic examination and pan-colonic or IRCI involvement on imaging by colonoscopy or CT
Consider CTA, MRA, or mesenteric angiography
Transfer to intensive care unit
Emergent surgical consultation
Supportive care, correction of cardiovascular abnormalities, volume replacement and broad-spectrum antimicrobials
Surgical intervention, if possible
* Risk factors associated with poor outcome: male gender, hypotension (SBP < 90 mm Hg), tachycardia (HR > 100 beats per min), abdominal pain without rectal bleeding, BUN > 20 mg/dl, Hgb < 12 g/dl, LDH > 350 U/l, serum sodium < 136 mEq/l (mmol/l), WBC > 15 x 10^9/cmm

Treatment

➢ Supportive care

- NPO and observation if there is no evidence of colon perforation, necrosis, or gangrene.
- Intravenous fluids should be given to ensure adequate colonic perfusion.
- NGT should be inserted if an ileus is present
- Any precipitating conditions should be treated, and medications known to promote intestinal ischemia (vasopressors, digitalis) should be promptly discontinued if feasible.
- Cardiac function and oxygenation should be optimized.

● Most patients with nonocclusive colonic ischemia improve within one or two days and have complete clinical and radiologic resolution within one to two weeks. The patient should be monitored for persistent fever, leukocytosis, peritoneal irritation, protracted diarrhea, or GIB.

Treatment

- **Supportive care**
  - **Antibiotics**
    - There is no strong evidence supporting the routine use of antibiotics for the treatment of all patients with colonic ischemia, guidelines that suggest empiric broad-spectrum antibiotics for patients with **moderate and severe** colonic ischemia
    - Regimen include: an ***anti-anaerobic agent plus a fluoroquinolone or an aminoglycoside or a third-generation cephalosporin***.
    - recommends that antimicrobials be continued for at least 72 h, If the patient has not clinically improved, consult with an infectious disease expert. If the patient is symptomatically improved after 72 h, a 7-day course of therapy should be considered.

Treatment

➢ Supportive care

- **Antithrombotic therapy**

✓ **Antithrombotic** therapy is **not indicated** for most patients with colonic ischemia, as the majority have nonocclusive ischemia.

✓ **Anticoagulant** therapy is indicated for patients who develop **colonic ischemia due to mesenteric venous thrombosis or related to mesenteric thromboembolism** (cardiac source).

✓ ***Recanalization of thrombosed mesenteric veins*** has been described following long-term anticoagulant therapy. patients with mesenteric vein thrombosis should be evaluated for ***hypercoagulability***

✓ **Antiplatelet agents are generally not indicated** in those without known peripheral vascular disease

Treatment

- **Supportive care**

Glucocorticoids are not recommended for CI, except when it is a due to **vasculitis**

NSAIDS are generally accepted to be a cause of colonic ulcerations, but one large trial of patients with CI showed that a lack of NSAIDSs use at the time of diagnosis was independently associated with severe disease (e.g., surgery and/or death).

This potentially protective effect of nonsteroidal anti-inflammatory drugs was an indirect observation with no further trials to date

Treatment

➢ Ongoing monitoring

- The patient should be counseled to avoid dehydration, constipation, and overly aggressive treatment of hypertension, particularly in the setting of illness or exercise

- Medications should be reviewed.

- It remains unclear which patients with colonic ischemia should undergo evaluation for hypercoagulability.
  - ✓ Routine **evaluation for hypercoagulability** is not necessary but may be reasonable in younger patients (<40 years of age) and those with recurrent colonic ischemia.

Treatment

- **Abdominal exploration**

Table 9. Indications for surgery in colonic ischemia

Acute indications
Peritoneal signs
Massive bleeding
Universal fulminant colitis with or without toxic megacolon
Portal venous gas and/or pneumatosis intestinalis on imaging
Deteriorating clinical condition
Subacute indications
Failure of an acute segmental ischemic colitis to respond to treatment within 2–3 weeks with continued symptoms or a protein-losing colopathy
Apparent healing but with recurrent bouts of sepsis
Chronic indications
Symptomatic colon stricture
Symptomatic segmental ischemic colitis

Treatment

- **Abdominal exploration**
  - Surgery is required in up to 20 percent of cases.
  - Clinical suspicion of ischemia (eg, ongoing pain that is out of proportion to clinical examination, hemodynamic instability) is a common indication for surgical exploration.
  - radiologic evidence of bowel necrosis or lesser degrees of ischemia in patients who do not respond appropriately to nonsurgical supportive care.
- Prior to abdominal exploration (open or laparoscopic), **bowel preparation should not be used**, as it can precipitate perforation or toxic dilation of the colon.
- In experienced hands, **laparoscopic colectomy**, is an option and can be avoids major wound complications.
- Once the abdomen is exposed (open or laparoscopic), the bowel should be systematically inspected from the ligament of Treitz to the peritoneal reflection overlying the rectum.

Treatment

- **Abdominal exploration**

Table 11. Risk factors for perioperative mortality

Low output heart failure (e.g., cardiac ejection fraction <20% on echocardiogram)
Acute kidney injury
Subtotal or total colectomy
Lactate >2.5 mmol/l
Pre- and intraoperative catecholamine administration

Risk factors	Mortality
0	10.5%
1	28.9%
2	37.1%
3	50.0%
4	76.7%
5	100.0%

For each risk factor, one point is given (142).

Postoperative care and follow up

- Following abdominal exploration or colon resection, the patient should be returned to ICU setting for hemodynamic support and monitoring.
- For patients who have undergone colectomy requiring ileostomy or colostomy, ostomy closure should be delayed for four to **six months**.
- Up to two-thirds of patients never proceed to reversal because of comorbid conditions

Mortality

* Most of the patients with CI **recover within 1 to 2 week** and the **overall mortality is almost 10%.**
* As a general rule, **non gangrenous** colonic ischemia is associated with **low mortality (<5 %)**
* The need for **surgery** increases the rates of morbidity and mortality. Approximately **10-20%** of patients develop colonic necrosis and gangrene and need surgery.
* patients with involvement **isolated to the right colon** had a **worse outcome**, with a **5X higher rate of surgery** and **2X higher mortality;** because right colonic ischemia is due to SMA insufficiency and is associated with diffuse small intestinal ischemia and shock

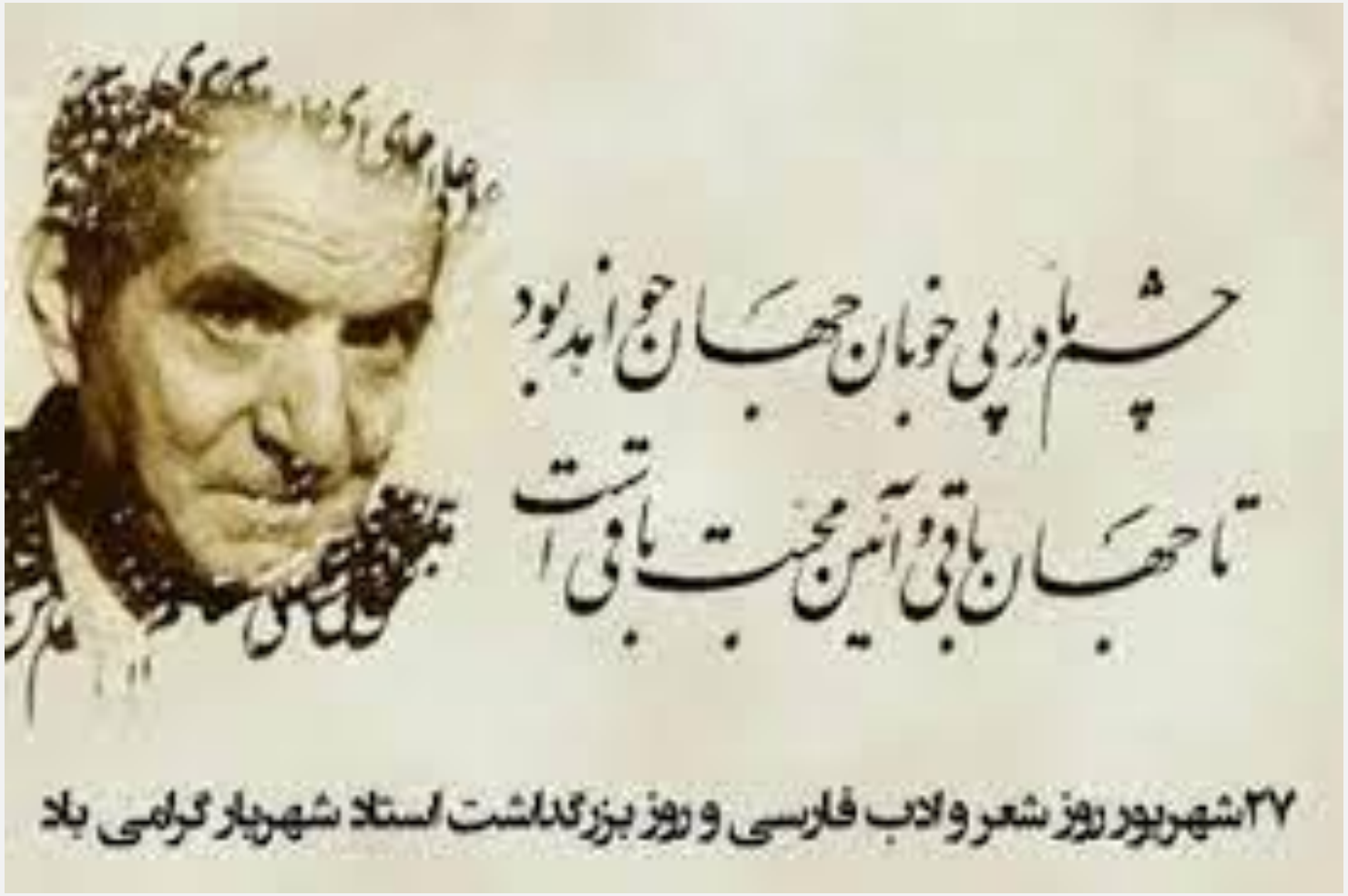
چشم ما در پی خوبان جهان جو امید بود
تا جهان باقی و آیین محبت باقی است
۲۷ شهریور روز شعر و ادب فارسی و روز بزرگداشت استاد شهریار گرامی باد

Thanks for listening, means a lot!